

Case Reports from Senecavirus A

Chris J. Rademacher, DVM

Senior Clinician - ISU Swine Extension Veterinarian

ISU College of Veterinary Medicine - VDPAM

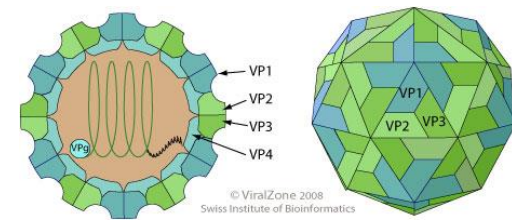
Senecavirus A = Seneca Valley Virus

Acknowledgements

- *Dr. Pablo Pineyro*
- *Dr. KJ Yoon*
- *Dr. Darin Madson*
- *Dr. Daniel Linares*
- *Dr. Rachel Derscheid*
- *Dr. Kent Schwartz*
- *Dr. Rodger Main*
- *Dr. Pat Halbur*
- *Dr. Derald Holtkamp*
- *Dr. Paisley Canning*
- *Dr. Jessica Bates*
- *Dr. Abbey Canon*
- *Dr. Dave Baum*
- *Dr. JQ Zhang*
- *Dr. Phil Gauger*
- *Dr. Karen Harmon*

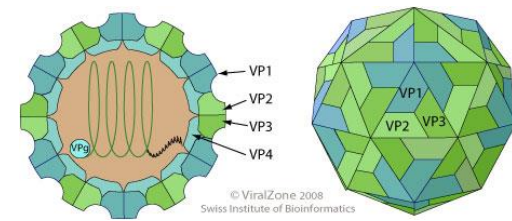


Seneca Virus A (Seneca Valley Virus)



- Senecavirus A is a non-enveloped single-stranded RNA virus of the family *Picornaviridae*.
- **Foot and Mouth Disease Virus (FMDV)** and **swine vesicular disease virus (SVDV)** is also a member of this same viral family.

Seneca Virus A (Seneca Valley Virus)



- Disease has been reported in the United States, Canada, Australia, Italy, New Zealand and most recently in Brazil.
 - Farm outbreaks in the United States are sporadic (less than 20 have occurred in the last 3 decades)
- In the last 5 years and prior to these recent outbreaks, Senecavirus A has been found in North Carolina and Illinois.

Is Senecavirus A really causing Idiopathic Vesicular Disease?

Koch's postulates:

1. the microorganism or other pathogen must be **present in all cases of the disease**
2. the pathogen can be isolated from the diseased host and **grown in pure culture**
3. the pathogen from the pure culture must **cause the disease when inoculated into a healthy, susceptible laboratory animal**
4. the pathogen must be **re-isolated** from the new host and **shown to be the same** as the originally inoculated pathogen

(Maryland University BSCI 424)

Is Senecavirus A really causing Idiopathic Vesicular Disease?

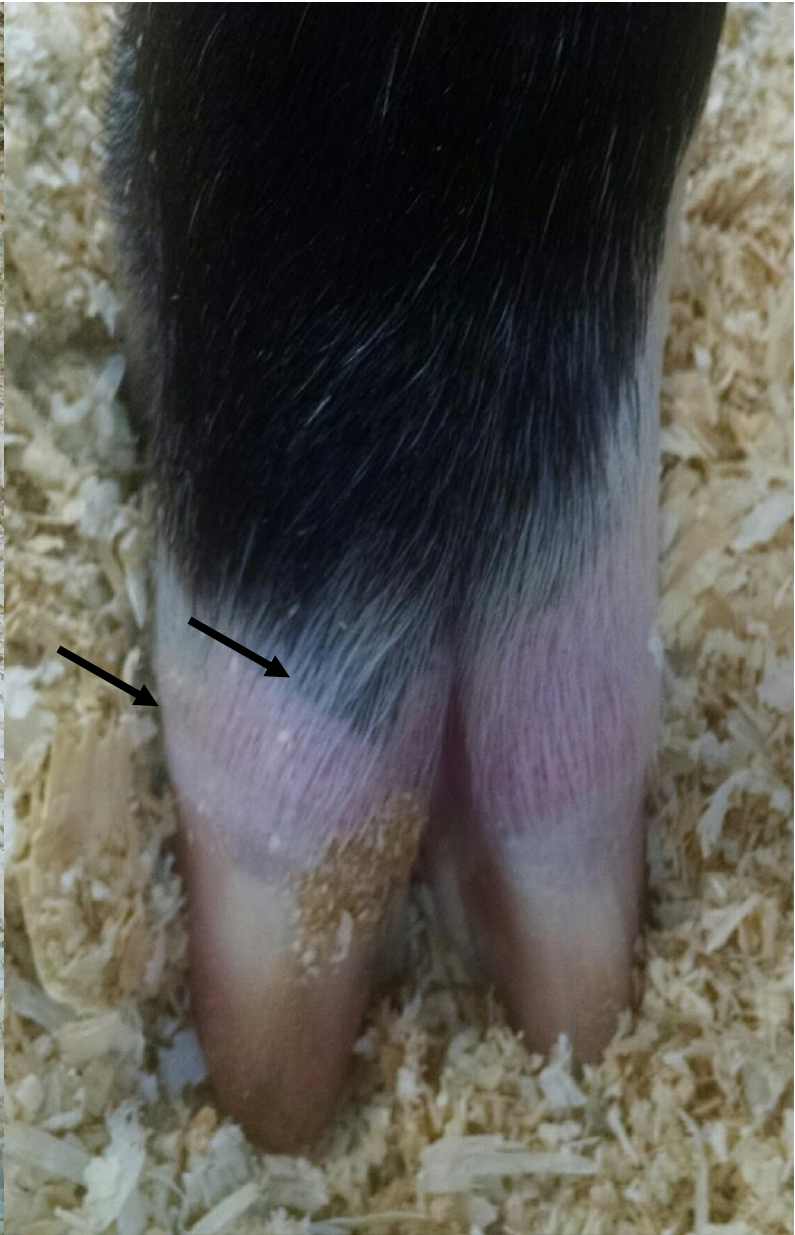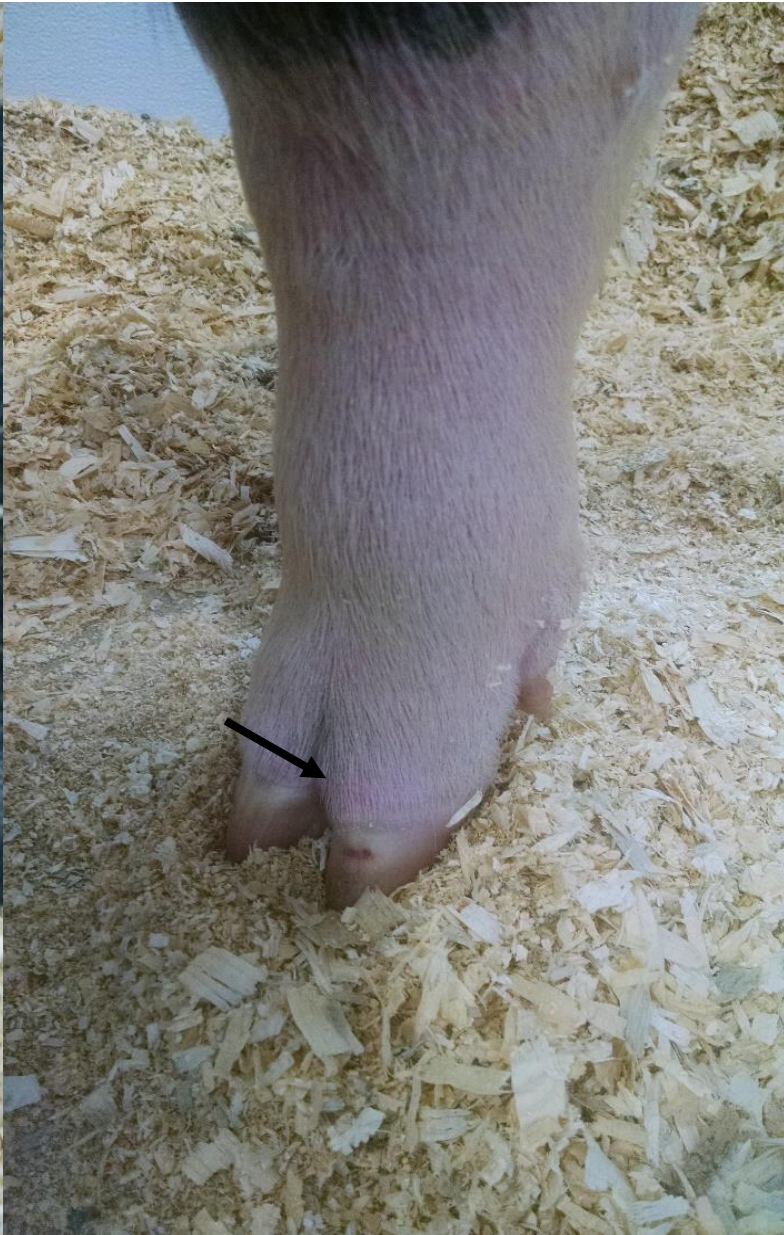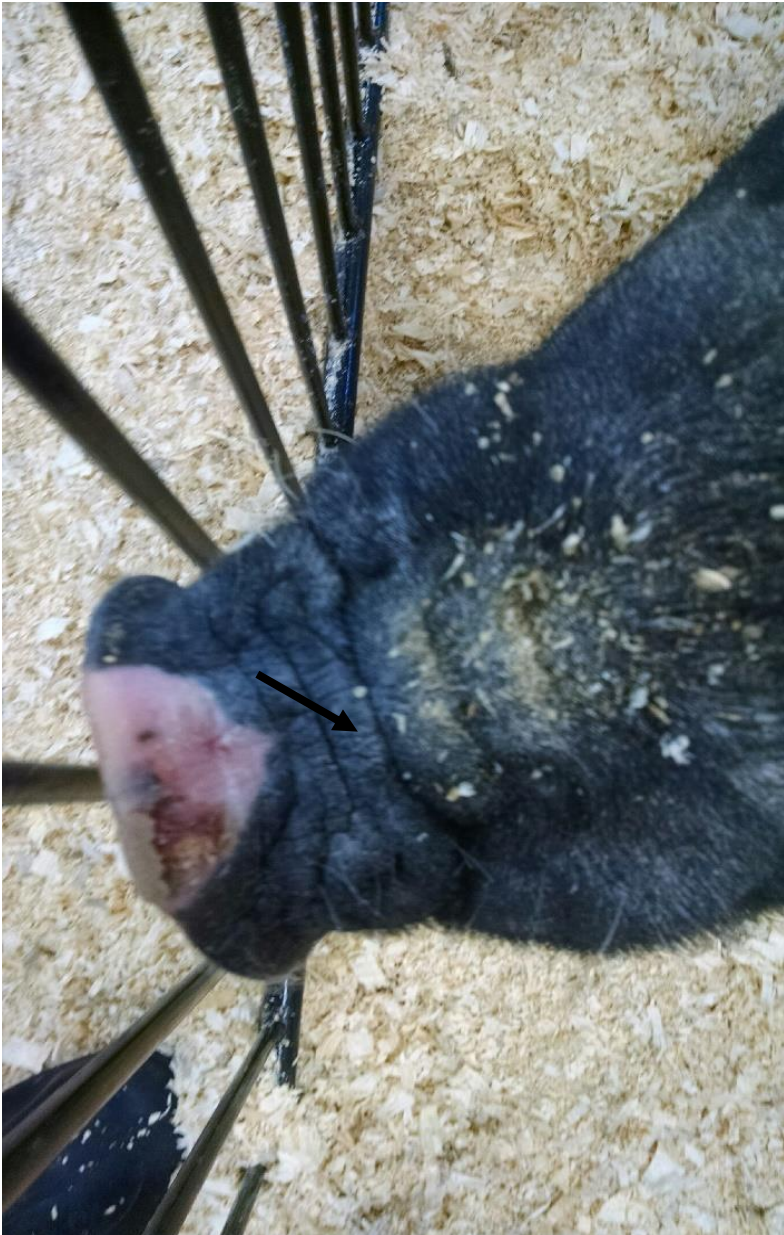- Koch's postulates have NOT been fulfilled for Senecavirus A and Idiopathic Vesicular Disease
- Several attempts at reproducing the disease
 - **Seroconversion** (production of antibodies) occurs
 - But **CANNOT reproduce clinical signs** consistent with Vesicular Disease

Case Reports: Growing Pigs

Senecavirus A Cases

- Started with 2 calls about exhibition pigs – July 21st
 - Reports of sudden lameness, redness around hoof
- Anecdotal reports of hoof lesions
- Both cases occurred after stressful event
 - Transportation

Exhibition Swine July 8 – 13 – Acute presentation



Senecavirus A Cases – Exhibition Swine

- State Veterinarian was contacted and **Foreign Animal Disease (FAD)** investigation initiated
 - FAD investigation conducted by state veterinary authorities
 - State personnel travel to site, examine animals and take samples
 - Samples then submitted to Plum Island to test for non-routine swine pathogens

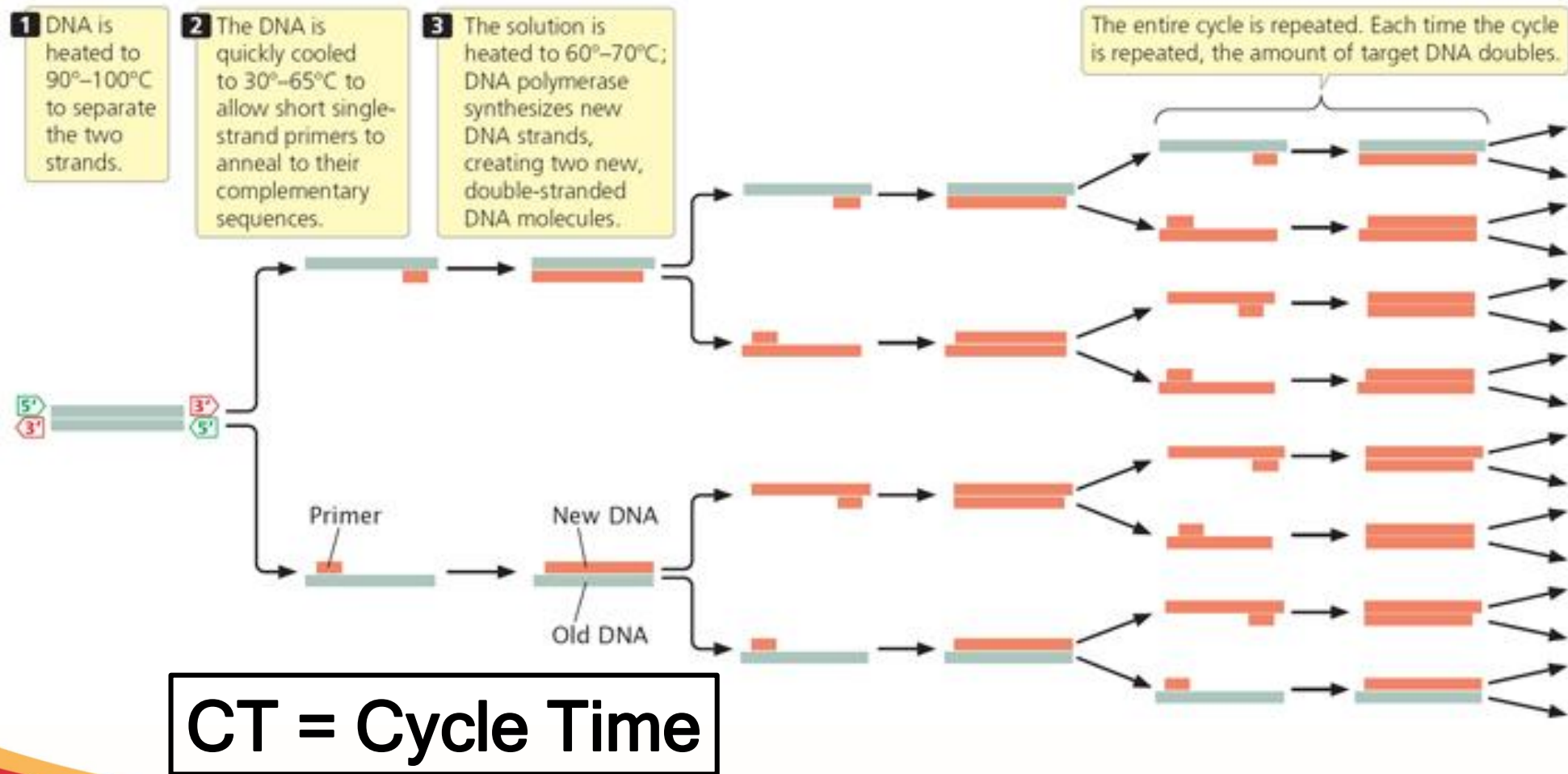
What other swine pathogens (FAD) to test for?

- **Foot and Mouth disease** (Picornavirus)
- **Swine Vesicular Disease** (Picornavirus)
- **Vesicular Exanthema of Swine** aka. San Miguel Sea Lion Viral Disease (Calicivirus – resp dx in cats)
- **Vesicular Stomatitis Virus** (Rhabdoviridae, same as Rabies)

- (Exhibition #1) - 7/21/15

Pig		Sample type	Test results				
		SV-A (SVV) rRT-PCR Seneca	FMD rRT-PCR Foot and Mouth	SVD rRT-PCR Swine Vesicular Disease	VES rRT-PCR Vesicular Exanthema of Swine	VSV (IND1) rRT-PCR Vesicular Stomatitis Virus	VSV (NJ) rRT-PCR Vesicular Stomatitis Virus
161	Swab	Positive	Negative	Negative	Negative	Negative	Negative
	Scrapings	Positive	Negative	Negative	Negative	Negative	Negative
162	Swab	Positive	Negative	Negative	Negative	Negative	Negative
	Swab	Positive	Negative	Negative	Negative	Negative	Negative
	Scrapings	Positive	Negative	Negative	Negative	Negative	Negative

What is a PCR Test?



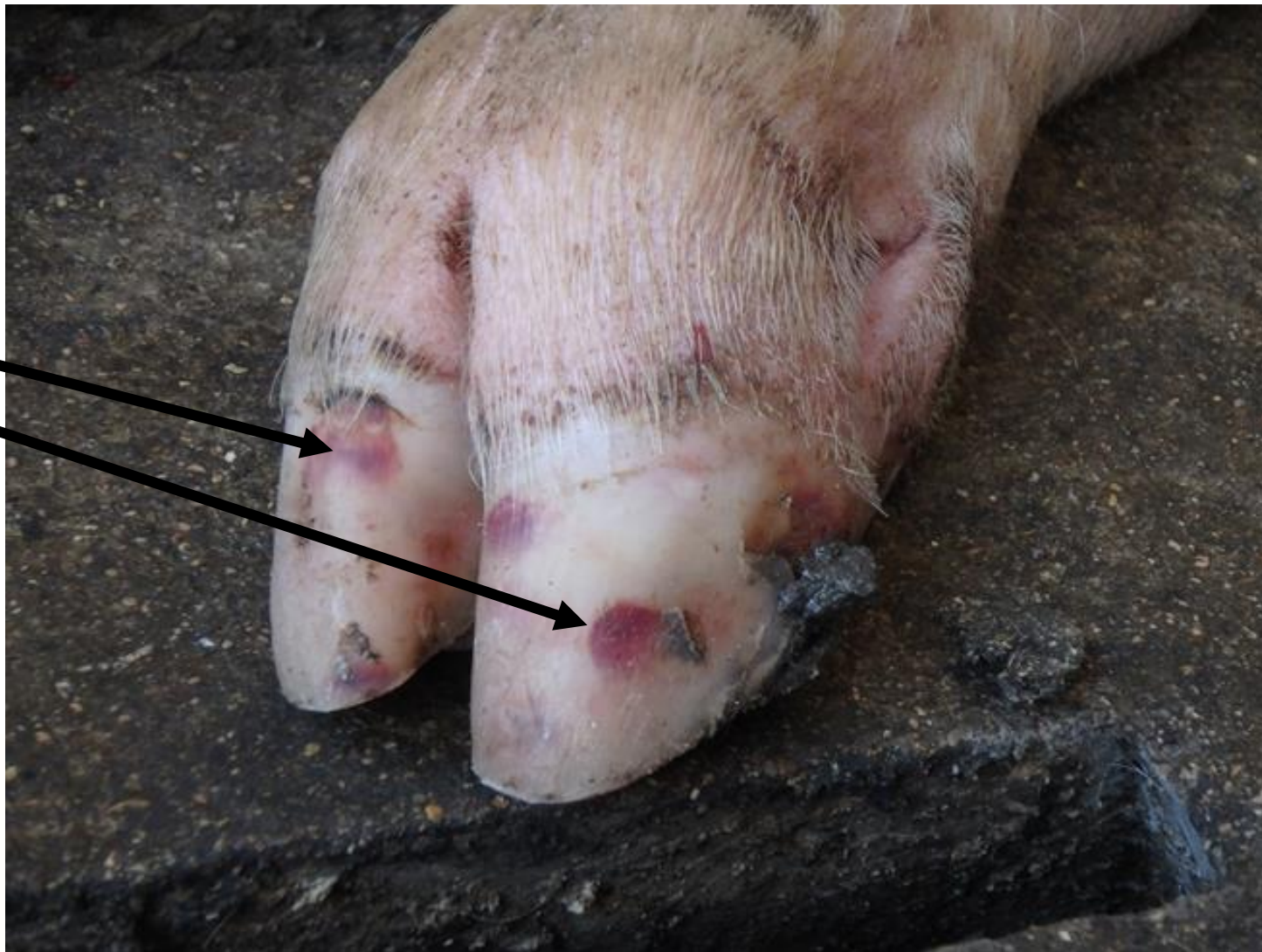Case 2: Commercial Finishing Herd- July 22nd

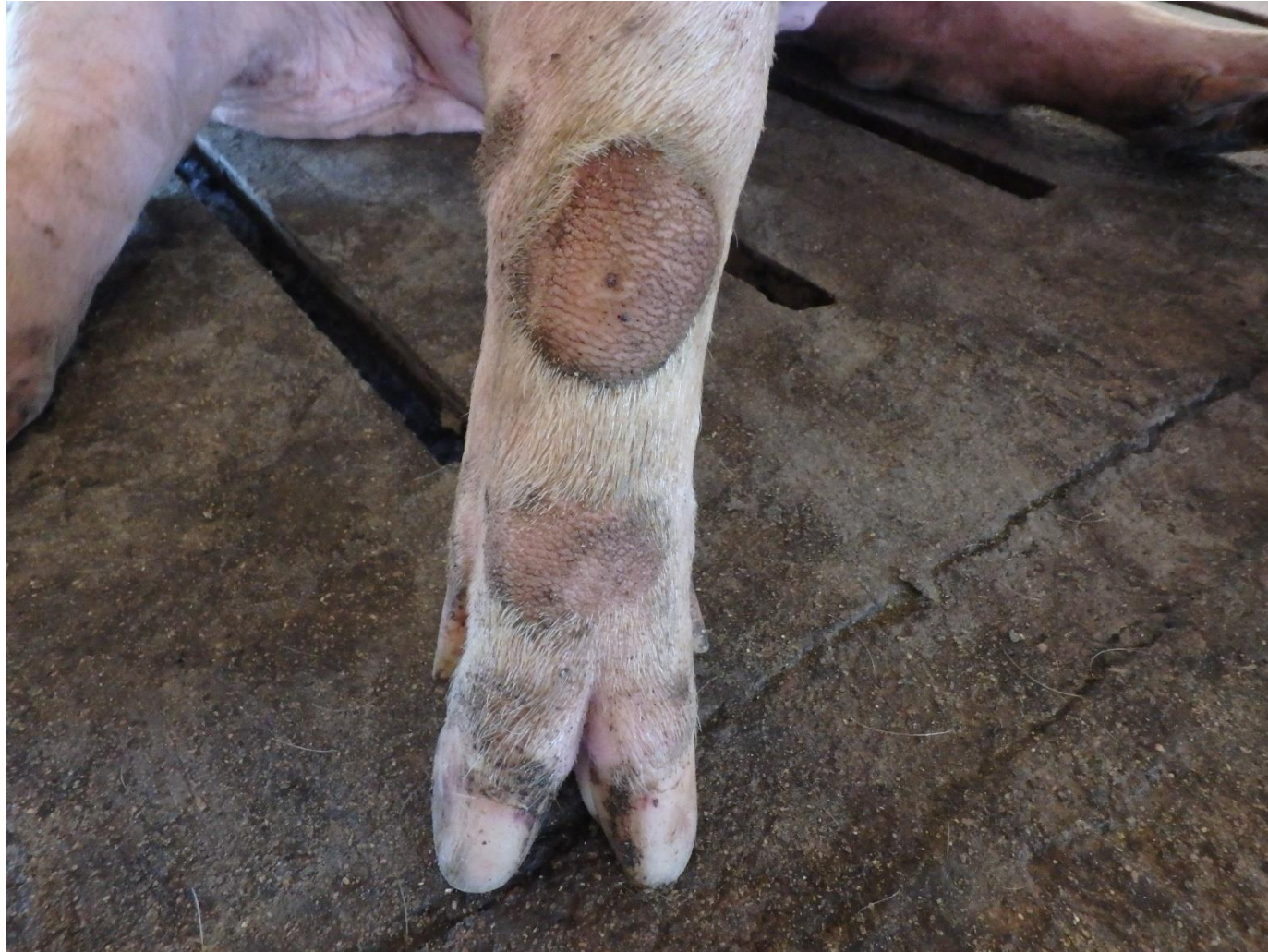- 1200 head finishing barn with report of acute lameness and vesicular lesions on snout and feet.
 - 20-30% prevalence initially (overnight)
 - Market weight animals
- Vet reported to state veterinarian, FAD investigation conducted – Negative for vesicular diseases
 - Positive for Seneca Valley Virus (both ISU and FADDL)

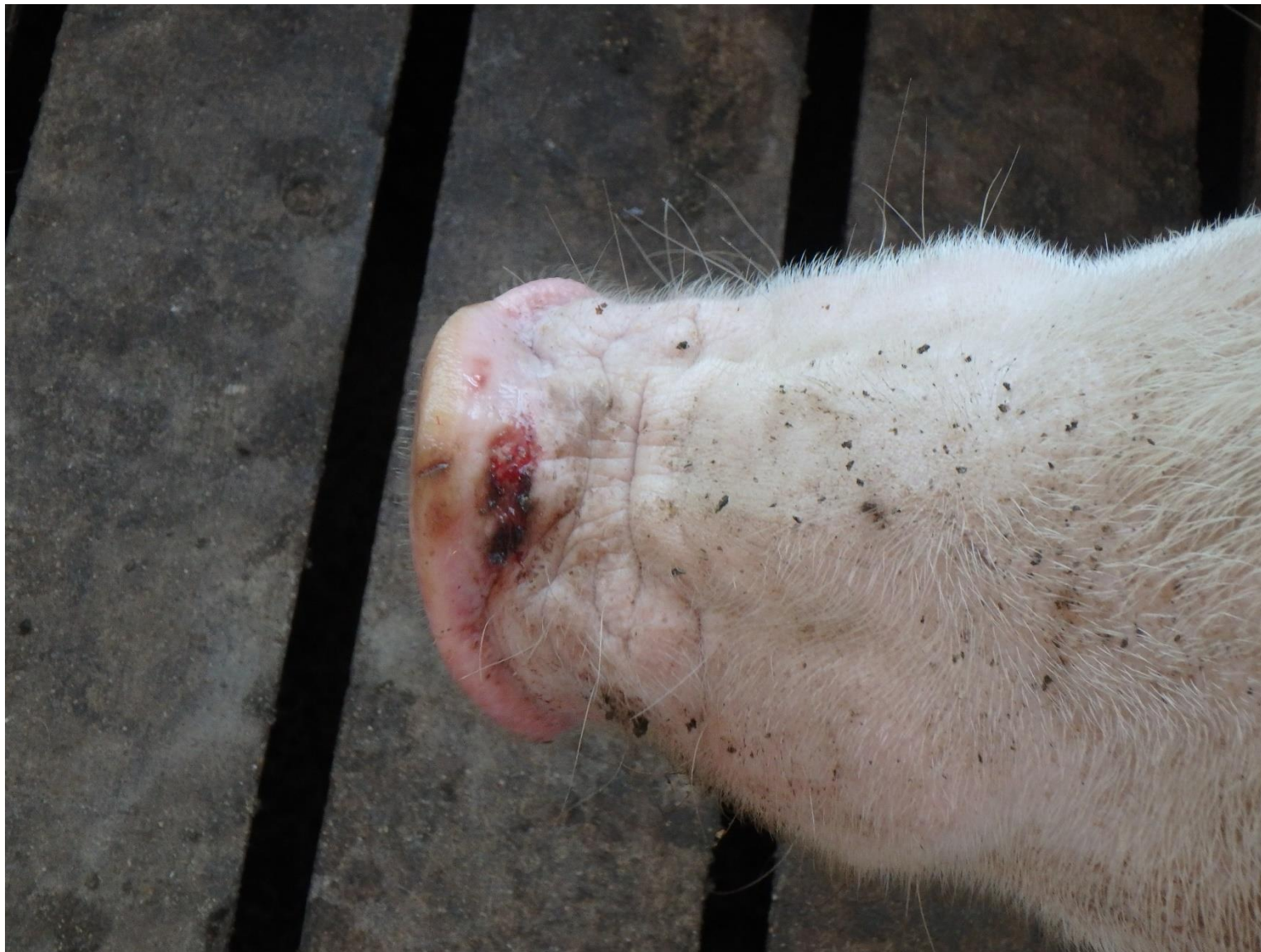Case 2: Commercial Finishing Herd - July 15th

- *First cut of pigs to go to market was July 10th*
 - *Dirty market truck*
 - *Commercial loading crew*
- First clinical signs reported on July 15
- Over next 10-14 days
 - 80-90% of pigs had some sort of lesions
 - Vesicular lesions or lameness
 - “Pigs crawling to the feeders”

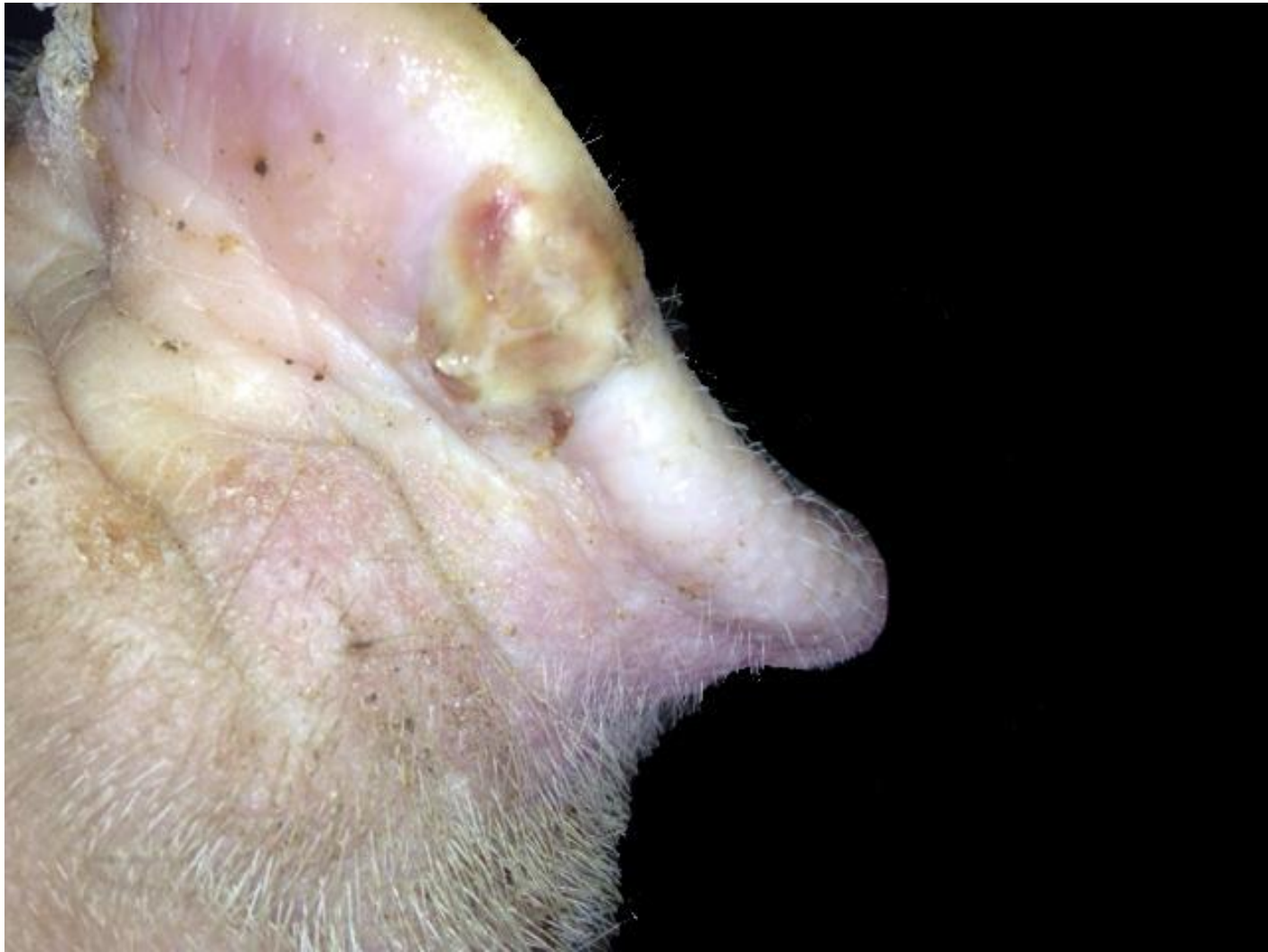Deep nail bed
hemorrhages



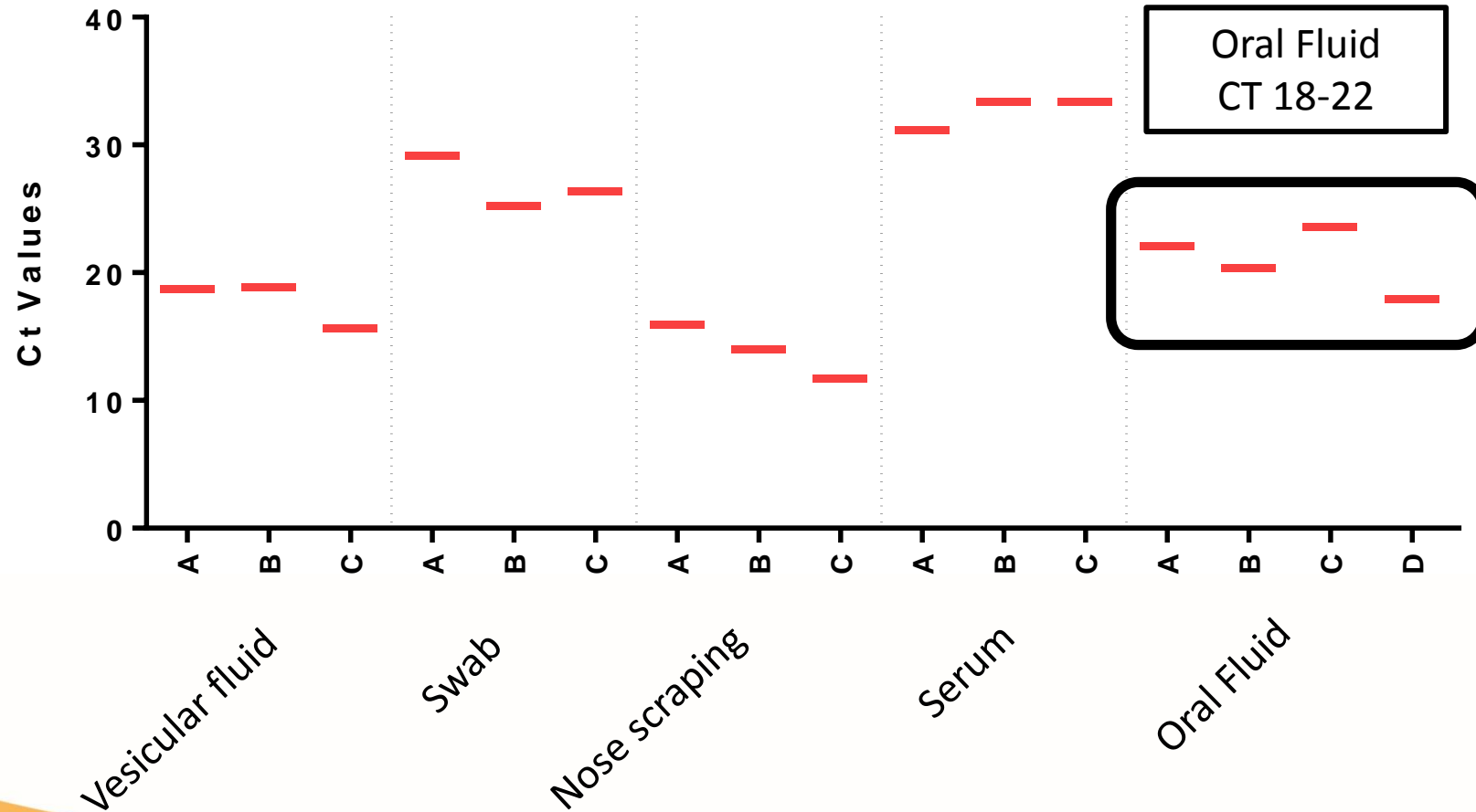




IOWA STATE UNIVERSITY
Extension and Outreach



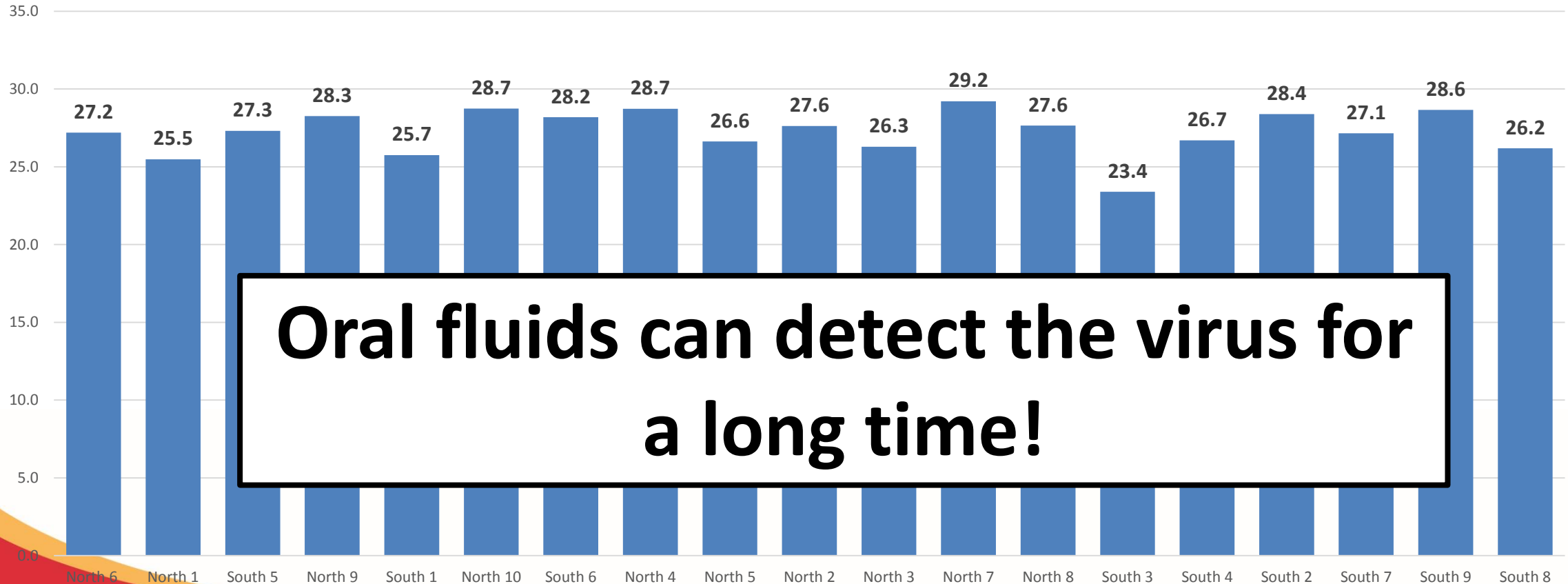
Commercial Finishing herd, 7/29/15 – 14 days into outbreak



Lower CT = Higher amounts of virus

Oral Fluids – 4 weeks into break

Oral Fluid CT - 4 weeks post break



Oral fluids can detect the virus for a long time!

Finishing Case

- Allowed 30 days for pigs to heal all the lesions and lameness subside.
- Sold all the remaining pigs without incidence.
 - Good communication with Packer and FSIS
- Second finishing case
 - Only 10-15% of pigs affected
 - Sold them 2 weeks later.

Case Report: Senecavirus A in Sow Farms

Seneca Virus Breeding Herd Cases

- Week of August 17th
 - Reports of high neonatal morbidity and mortality in pigs less than 7 days.
 - With or without diarrhea (more common with diarrhea)
 - Not usually finding much for other diarrhea agents
 - Some sows with high fevers early on (104-106^oF)
 - Some sows not eating fully (not much for off feed)
 - Mortality is short lived (4-7 days)

Seneca Virus Breeding Herd Cases

- With descriptions similar to these, pathologists began to run SVV PCR on various samples from submitted cases → started finding positives!!
- Upon further investigation, then finding evidence of vesicular disease in breeding age animals.
 - 10-40% prevalence
 - Vesicles or coronary band lesions
 - NO LESIONS in young pigs, Gross or Histologically.

Breeding Herd Lesions

- Lesions in sows in farrowing rooms
 - Affected litters
 - Sows had a few vesicles on the nose
 - Lots of lesions on the feet
 - Coronary band ulcerations
 - Interdigital ulcers
 - Deep nail hemorrhages
 - Saw similar lesions in unaffected litters, just not as severe.
 - No lesions in the pigs at all

Breeding Herd Lesions

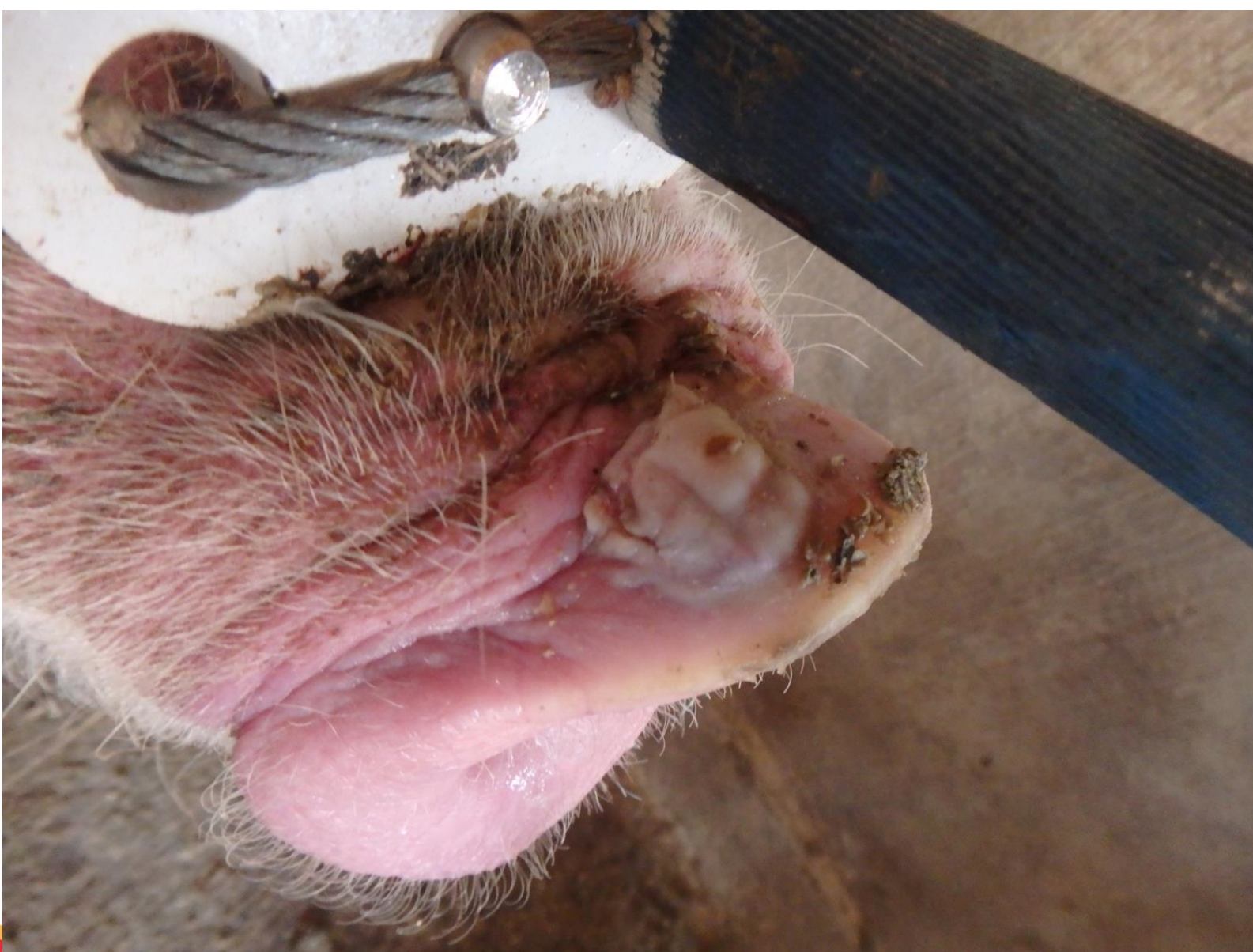- Gestation
 - Mostly all vesicular lesions
 - + or – feet lesions

Senecavirus A in neonatal pigs

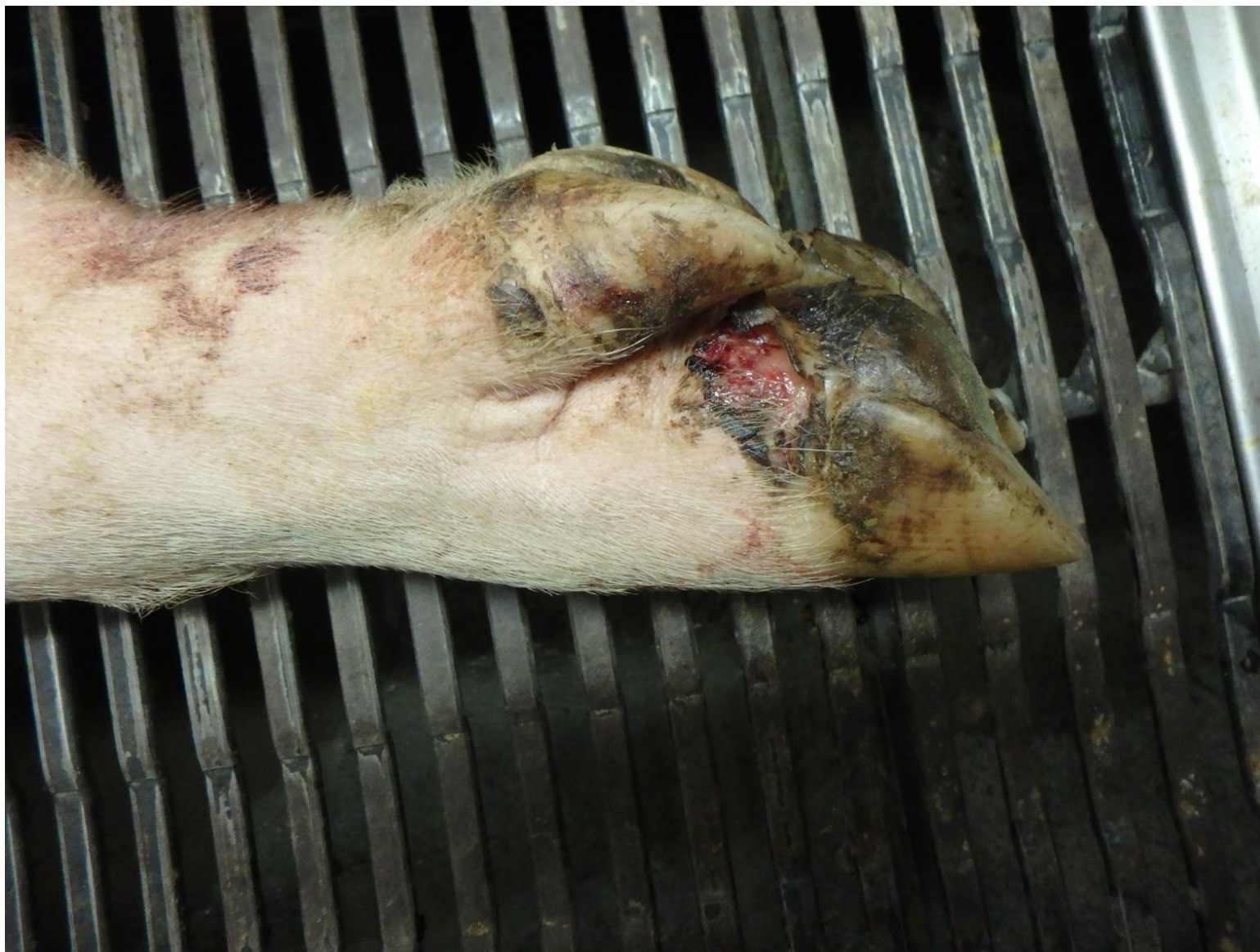

Senecavirus A in neonatal pigs

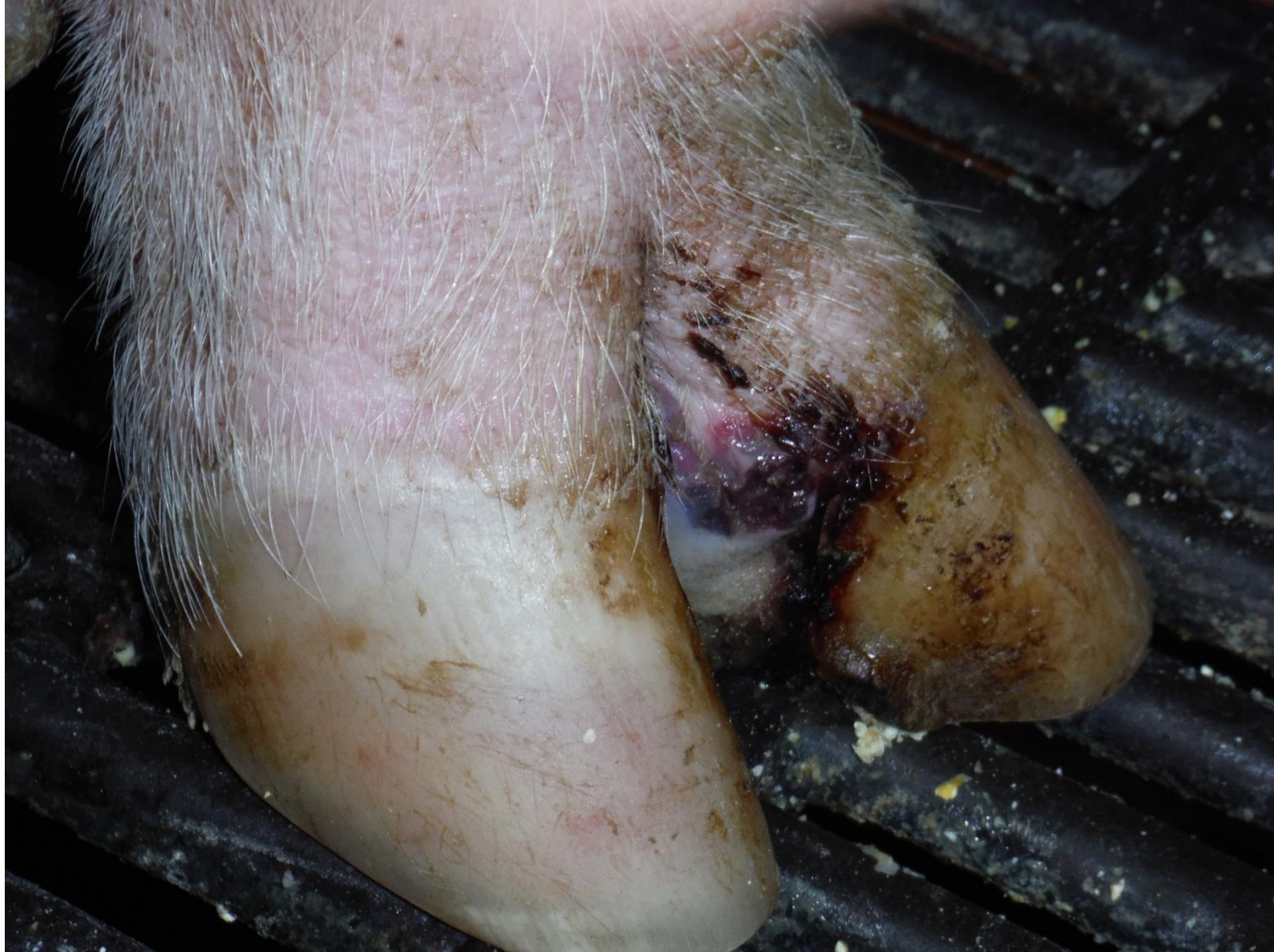



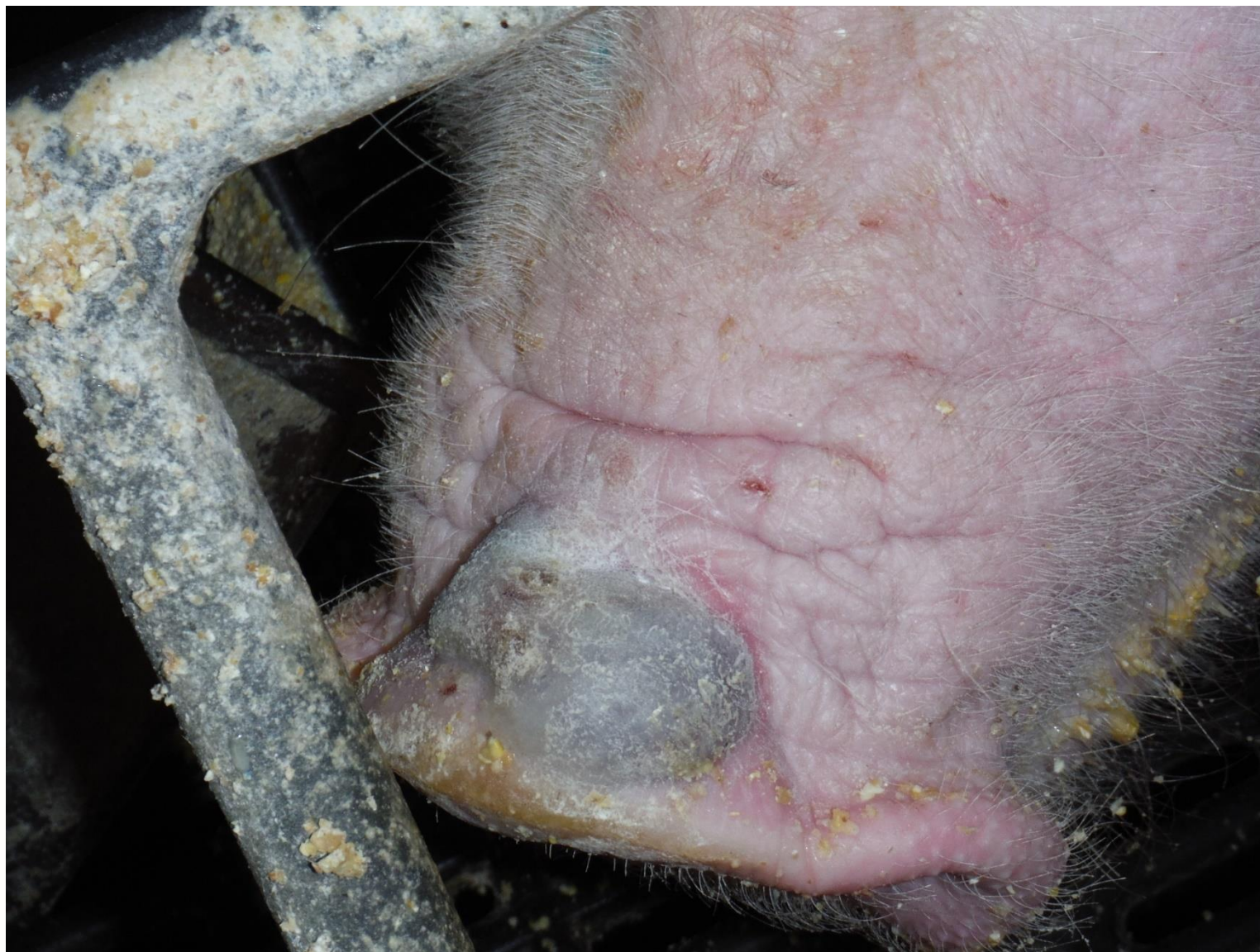IOWA STATE UNIVERSITY
Extension and Outreach

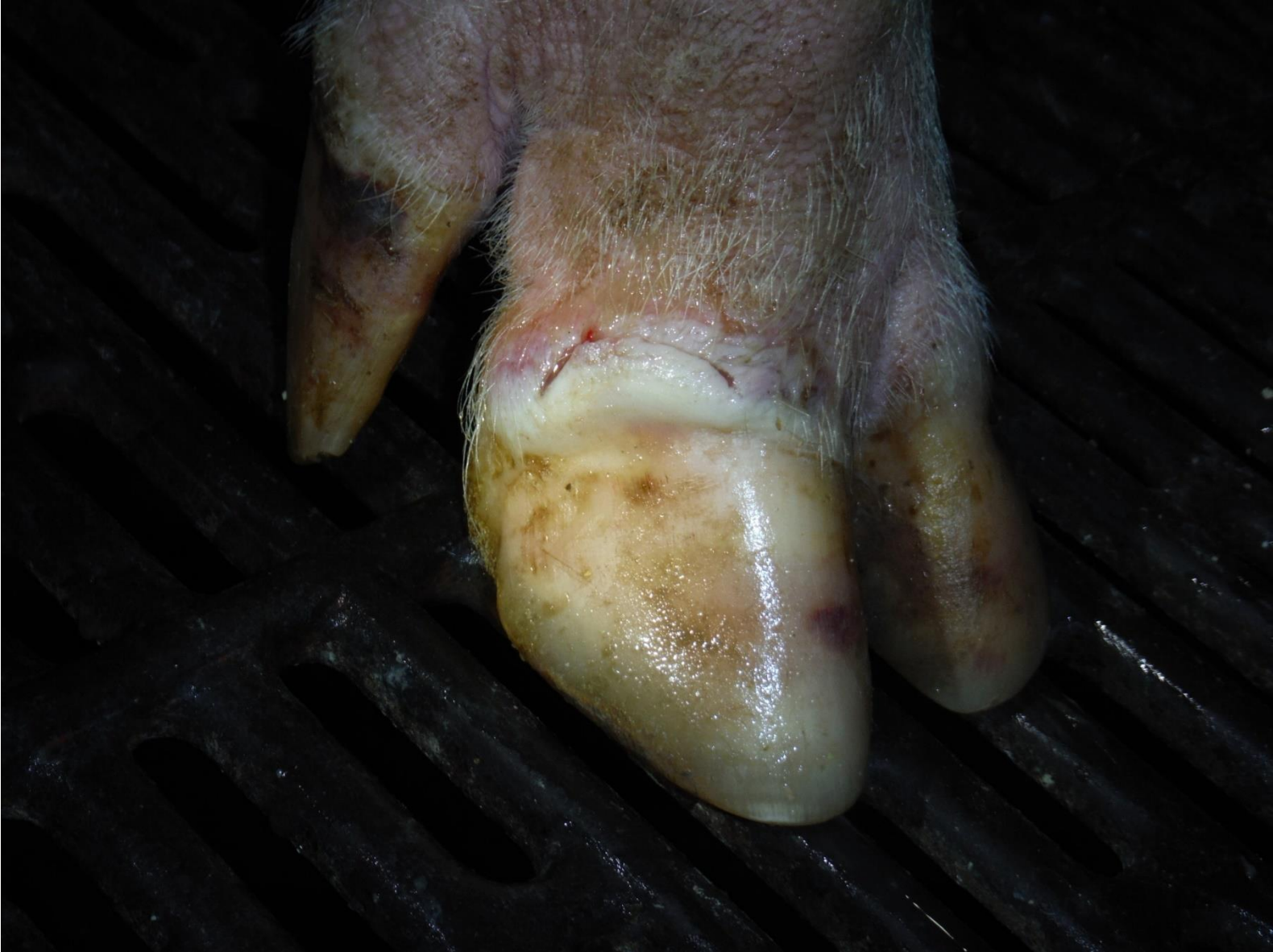

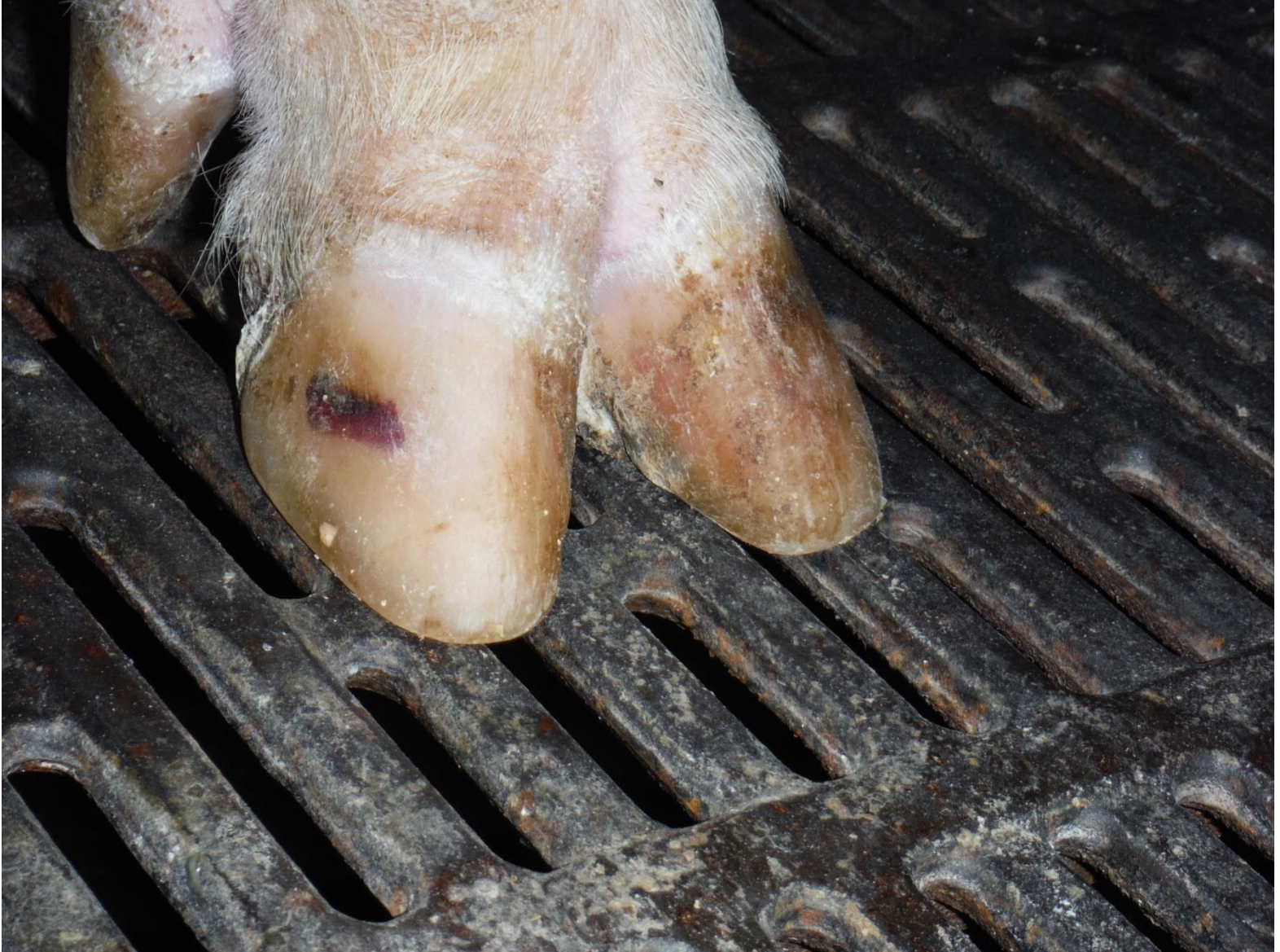IOWA STATE UNIVERSITY
Extension and Outreach



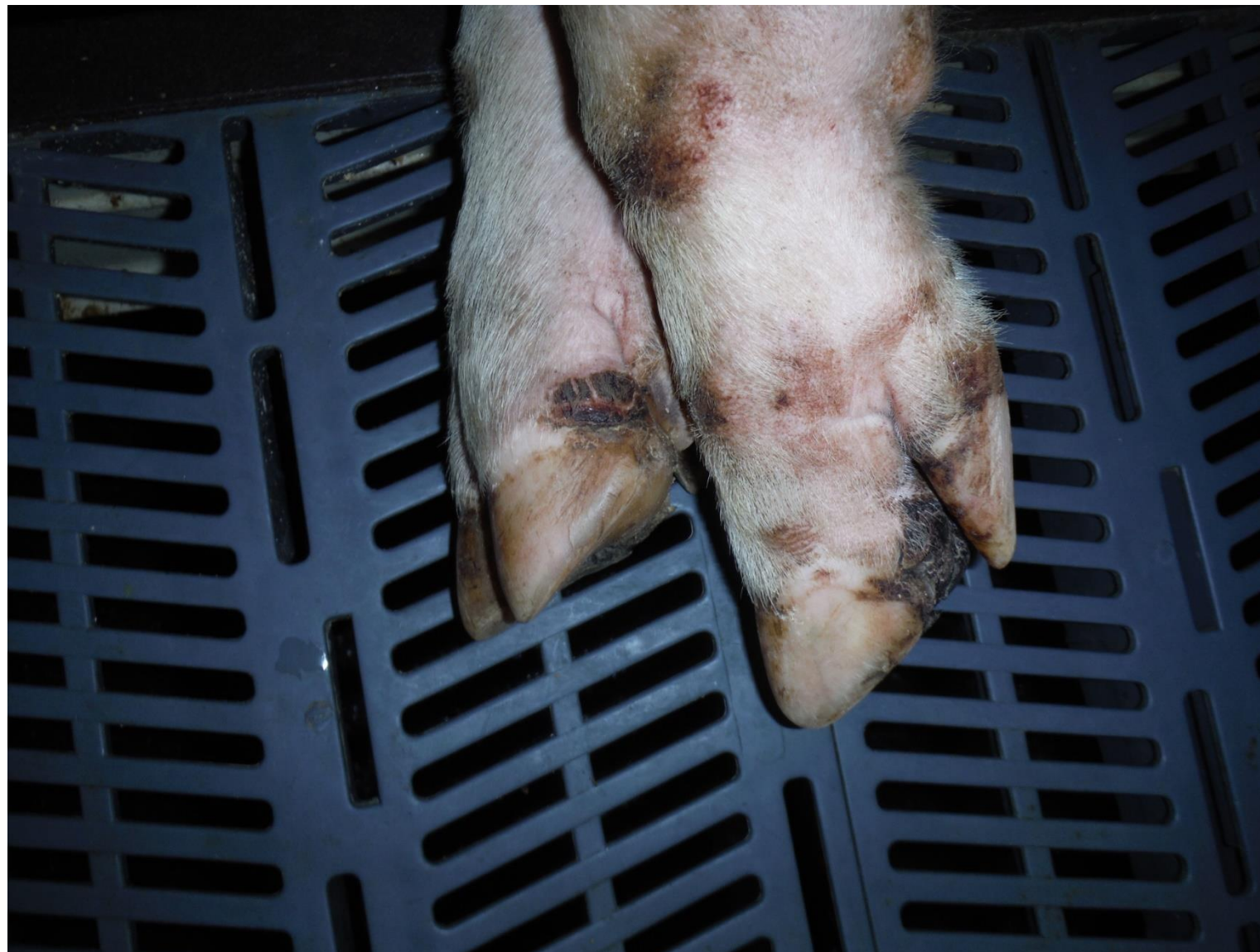IOWA STATE UNIVERSITY
Extension and Outreach





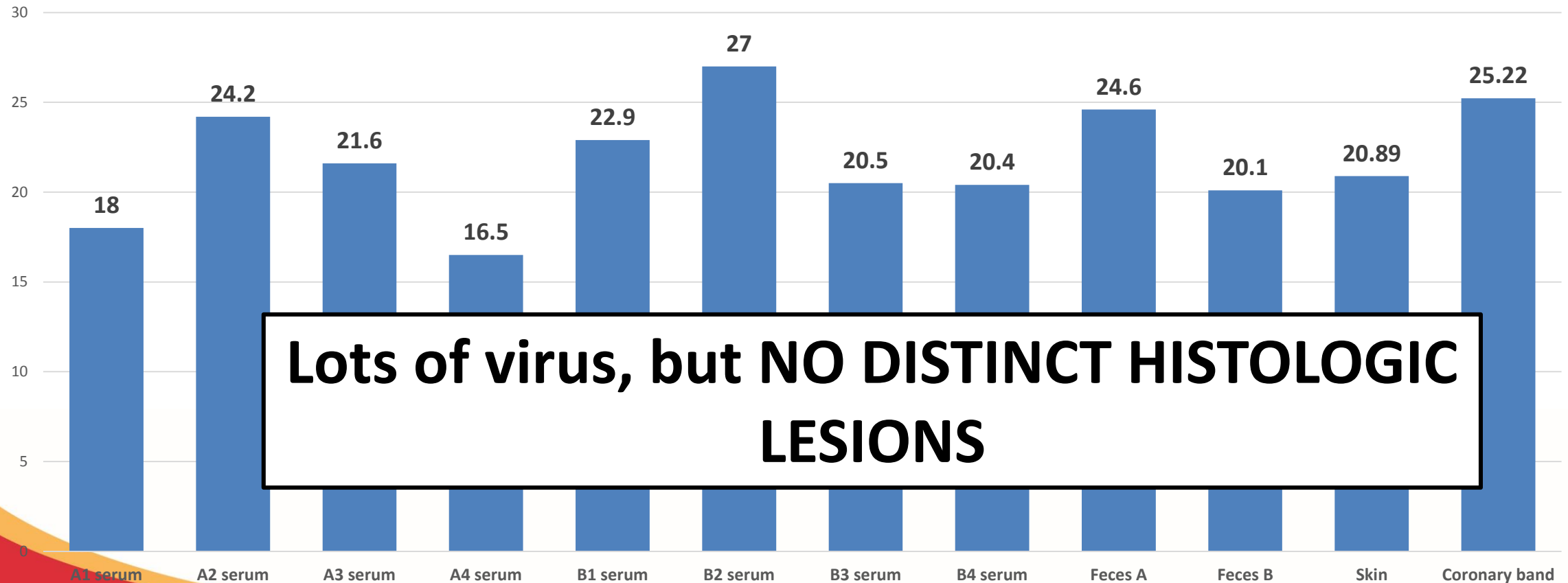


IOWA STATE UNIVERSITY
Extension and Outreach



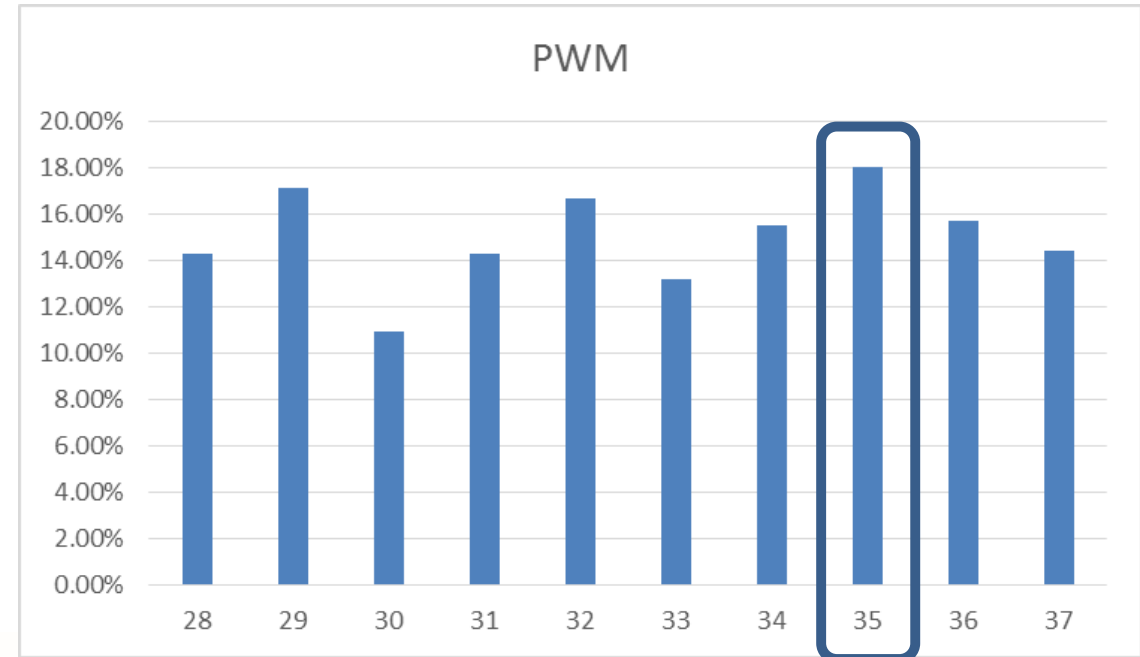
SVV PCR on neonatal pigs (less than 7 days)

Seneca Valley Virus PCR testing on neonatal piglets (less than 7 days of age)

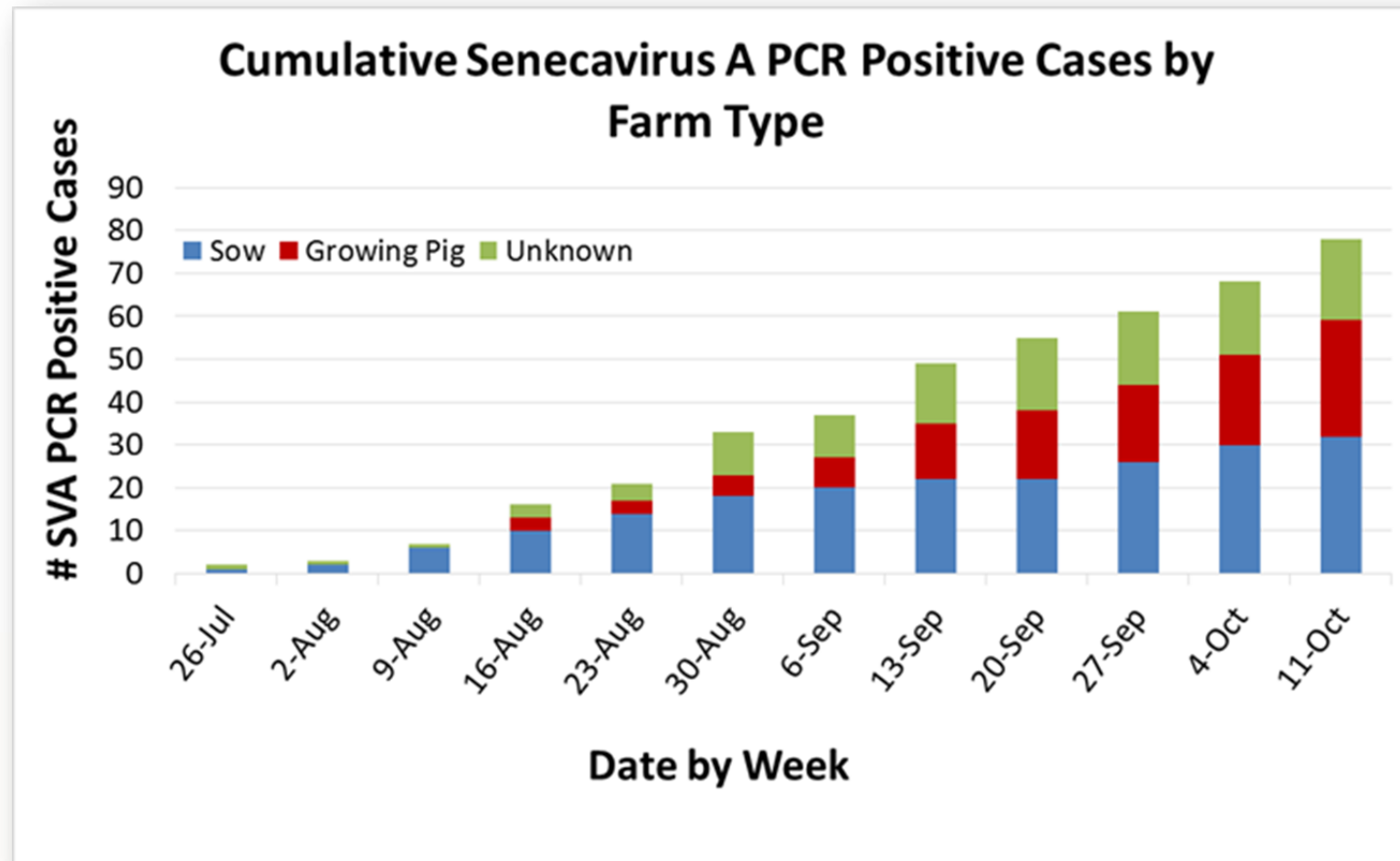


What's been the impact on % Pre-Wean Mortality (PWM)?

- Small increase (2-5%) in % PWM for 1 week.
- May double % PWM if there are other agents present
 - Clostridium difficile
 - Rota virus
- No reports of reproductive impact (Conc. Rate, Farrow Rate, Litter Size)



Current Status of Senecavirus A Diagnosis



Oral Fluid Survey (1108 samples from 241 cases)

From 8.24.15 through 8.31.15

State of Origin	Total Number of Positive Samples in Case
IL	2
IA	1
IN	2

241 cases with
1108 samples

1.2 % of cases and 0.45% of samples tested positive

Testing Available

- **Real Time PCR**
 - Same day if samples arrive by 11am
 - Main test currently relied on
 - Presence of nucleic material only
- Virus Isolation
- Sequencing
 - Whole genome and VP1
 - Next generation sequencing
- Serology (Antibodies)
 - SN and IFA – Currently being validated
 - ELISA – Under development
 - Indicates Past Exposure
- **Immunohistochemistry:**
 - Formalin fixed tissue on a slide, wash with fluorescent antibodies against SVV antigens
 - Viral antigen in association with tissue, ideally histopathological lesions

What should you do if you suspect SVA??

- If you see suspect lesions on nose and/or coronary bands?
 - Contact your veterinarian and State/Federal Officials
 - They will determine the next course of actions
- DO NOT attempt to sell pigs with active lesions.
 - Wait until they are completely resolved.
- See an increase in % PWM in neonatal pigs (less than 7 days)
 - **Look for vesicular lesions** → contact State/Federal Officials

Summary

- Seen a significant increase in cases of Idiopathic Vesicular Disease
 - Senecavirus A in all cases
- Senecavirus A in cases of increases in % PWM in neonatal pigs
 - Short duration (4-7 days)
- Clinical pictures match description of cases in Brazil over the past year.
- The virus may have changed from historical isolates.

Summary

- Must continue to be vigilant to work up cases as Foreign Animal Disease (FAD) to continue to rule out vesicular diseases that are FAD

Questions??